



PATIENT PRESENTING CLINICAL SIGNS

Dottie Sutherland Patient developed pain with the mouth about two weeks ago which seemed to respond to NSAID's but 5 days ago developed left eyelid swelling and a fluctuant swelling on top of the head which was drained two days ago and determined to be an abscess. It seems to be responding to cephalixin but owner though that she still was acting painful with eating as of yesterday.

SPECIES

Canine Abnormal PE/Chem/CBC/UA Results: Chem 10/CBC unremarkable

COMPUTED TOMOGRAPHIC STUDY OF THE HEAD

BREED

Plain and post contrast studies are available for review.

Standard Poodle

COMPUTED TOMOGRAPHIC FINDINGS

SEX

FS

Residual soft tissue swelling with strongly increased contrast enhancement is seen. Small loculated collections of fluid are noted within the left temporal and retrobulbar swollen soft tissues. No evidence of extension of the swelling of fluid into the retromolar area is noted. Foreign material is not detected on the available post contrast images.

AGE

5yr

Mild enlargement of the left retropharyngeal lymph node consistent with reactive changes is seen.

The skull and facial bones are unremarkable; no lysis or sequestering are identified. There is no evidence of a mass effect.

INTERPRETED BY

Nele Eley (Ondreka),
DVM Dr. med. vet.,
DipECVDI

The brain presents no deviation from normal anatomy and symmetry. The grey and white matter distinction and the neuroparenchyma attenuation are as expected. The distribution of contrast enhancement is within normal limits throughout the parenchyma and meninges. The ventricular system is non-dilated and within the limits of the expected volume and symmetry.

HOSPITAL NAME

Petroglyph Animal
Hospital

Thin and smoothly folded conchae and turbinates with even smooth mucosal lining. The osseous lining of the nasal cavities is intact.

Both temporomandibular joints present congruent joint spaces with even subchondral bone surfaces and are considered within normal limits.

REFERRING VET

Alice Ku

Both tympanic bullae are aerated, the mucosal lining is not seen, the bony wall is smooth and thin. The external auditory meatuses present within normal limits.

The salivary glands present within normal limits.

The visible dentition is within normal limits.

INVOICE

23660

COMPUTED TOMOGRAPHIC DIAGNOSIS

DATE

01/23/26

- Residual abscess tissue in left temporal and retrobulbar region, currently reduced after drainage and antibiotic therapy
- Mild reactive left retropharyngeal lymphadenopathy



PATIENT

- No evidence of extension into retromolar or adjacent deep retrobulbar spaces

Dottie Sutherland

INTERPRETATION OF FINDINGS & FURTHER RECOMMENDATIONS

SPECIES

Canine

The CT findings support presence of residual abscess tissue in the left temporal and upper retrobulbar region which appears to be reduced after drainage and antibiotic therapy, however residual infectious material or small pieces of foreign material cannot be completely excluded.

BREED

Standard Poodle

Continue current antibiotic therapy and monitor for clinical improvement. Consider follow-up imaging if swelling persists or if new clinical signs develop. Monitor ocular function due to mild retrobulbar involvement. Consider surgical exploration if abscess fails to resolve or recurs.

SEX

FS

AGE

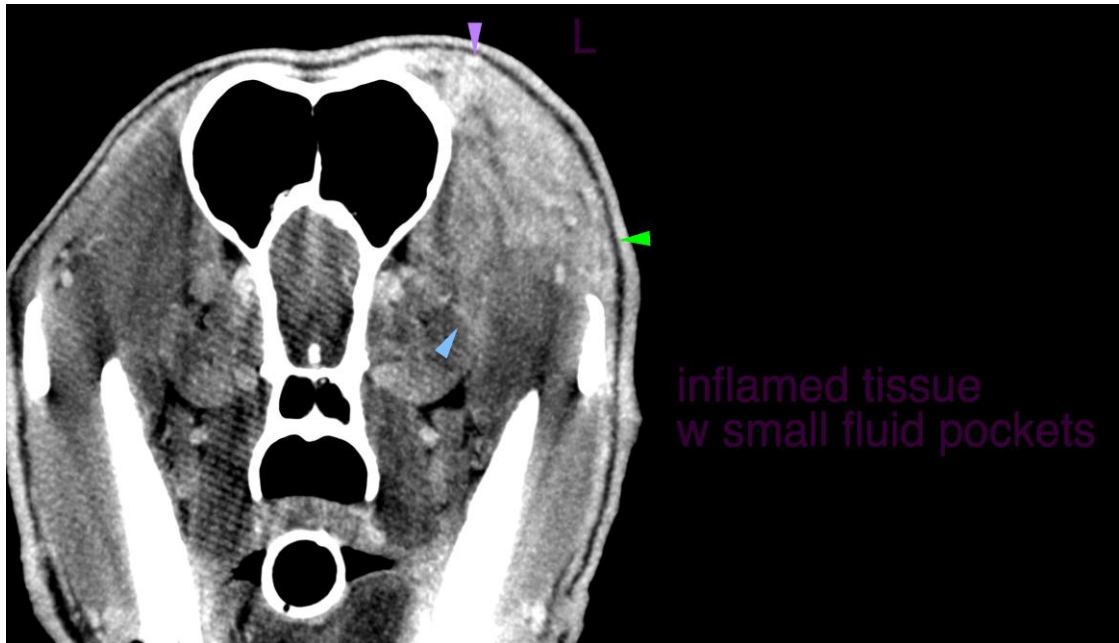
5yr

INTERPRETED BY

Nele Eley (Ondreka),
DVM Dr. med. vet.,
DipECVDI

HOSPITAL NAME

Petroglyph Animal
Hospital



REFERRING VET

Alice Ku

The information and recommendations provided are based on the images presented by the referring veterinarian. No evaluation can be communicated regarding pathology that was not visible in the image/video clips provided.

Thank you for this referral. If the clinical or image interpretation does not parallel your findings or if I can be of any further assistance please contact me.

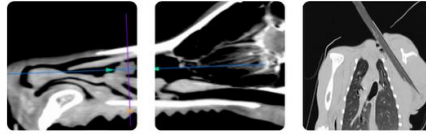
INVOICE

23660

Nele Eley (Ondreka), DVM, Dr. med. vet., DipECVDI
European Specialist in Veterinary Diagnostic Imaging, Cert. Radiology,
Senior lecturer University of Giessen/Germany, Veterinary Faculty, Department of Radiology.
info@sonopath.com

DATE

01/23/26



Teleradiology

Educational Teleconsultation Services™

PATIENT

Dottie Sutherland

SPECIES

Canine

BREED

Standard Poodle

SEX

FS

AGE

5yr

INTERPRETED BY

Nele Eley (Ondreka),
DVM Dr. med. vet.,
DipECVDI

HOSPITAL NAME

Petroglyph Animal
Hospital

REFERRING VET

Alice Ku

INVOICE

23660

DATE

01/23/26